

Original Research Article

The “Hamilton Deadlift”, a Novel Reduction Technique for Challenging Posterior Hip Dislocations: Case Report

Taylor Woolnough BMSc^a, Gwendolyn Lovsted BArch^a, and Colby Oitment MD, FRCSC^b

^aMichael G. DeGroote School of Medicine, McMaster University

^bDivision of Orthopedic Surgery, Department of Medicine, McMaster University

Abstract

This case report describes the first application of the “Hamilton Deadlift”, a novel reduction technique for challenging posterior hip dislocations. A 30-year-old female of large body habitus presented to the emergency department with a posterior hip dislocation after a high-speed motor vehicle collision. After two other closed reduction techniques were unsuccessful, the “Hamilton Deadlift” was successfully used to reduce the dislocated hip. The technique involves deadlift-like positioning, with the patient’s injured leg placed over the physician’s upper back. The physician then extends at the knees and hips to reduce the hip of the patient. Benefits of this proposed technique include the utilization of a familiar lifting pattern involving large muscle groups and possible execution without an assistant providing counter-traction. This technique may be useful in posterior native hip dislocations where more force generation is required or when the physician’s upper body musculature and ability to grip the injured leg prevent the application of more traditional methods. In the event of a failed reduction, application of the “Hamilton Deadlift” may prevent the need for muscle paralysis in the operating room or open reduction.

Keywords: Posterior hip dislocation

Corresponding author: Taylor.woolnough@medportal.ca

Introduction

Traumatic hip dislocations are devastating injuries that appear to be increasing in frequency in North America (1). Posterior hip dislocations represent 90% of all hip dislocations and largely occur due to motor vehicle collisions (1-3). Common associated injuries include ipsilateral femoral head, neck, and shaft fracture, knee injury, and sciatic nerve injury (4, 5). Late complications such as osteoarthritis and femoral head osteonecrosis may also occur following hip dislocation (6). Reduction is typically urgent as the incidence of sciatic nerve injury, chondrolysis, and femoral head avascular necrosis increase when reduction is delayed (7-10). During reduction, substantial force is required to overcome the muscles of the hip girdle and obstructing structures, such as the acetabular wall, labrum, and joint capsule (1-4).

A number of reduction techniques for posterior hip dislocation are available, including well-established methods like the Allis or Bigelow, or newer methods like the ‘Captain Morgan’ (10-13). While execution is variable, the cardinal movements of hip reduction are consistent: in-line traction, flexion, adduction, and internal rotation (14). Newer reduction techniques often focus on ergonomic friendliness for the practitioner; however, they may require unfamiliar positioning which can limit the force available for reduction and are thus not always successful (14-16). Surgical intervention is typically required in the case of failed closed reduction, therefore exposing patients to additional risks (1, 3). When one technique is unsuccessful, familiarity with additional reduction techniques may increase the likelihood of successful closed reduction—thereby avoiding the necessity of operative management (3, 4). The following case-report describes the successful application of an alternative reduction technique termed the “Hamilton Deadlift” and explores the potential risks and benefits of this novel technique.

Case Presentation

A 30-year-old female of large body habitus presented to the trauma bay following high-velocity motor vehicle collision. The patient had a visibly shortened right leg with her hip adducted and internally rotated, which is typical of a posterior hip dislocation. A right humerus deformity was also apparent. Initial radiographs demonstrated a posterior hip dislocation with an associated infrafoveal femoral head fracture (Fig. 1). A fracture of the humeral shaft and distal humerus were also seen on x-ray. No other significant injuries were appreciated. After discussing the risks and benefits of closed reduction, the patient was consciously sedated in the standard fashion. With the patient supine on a stretcher, the ‘Captain Morgan’ and Allis techniques were trialed and subsequently unsuccessful. Both techniques were difficult, in part due to the large leg size of the patient which made gripping of the leg difficult.

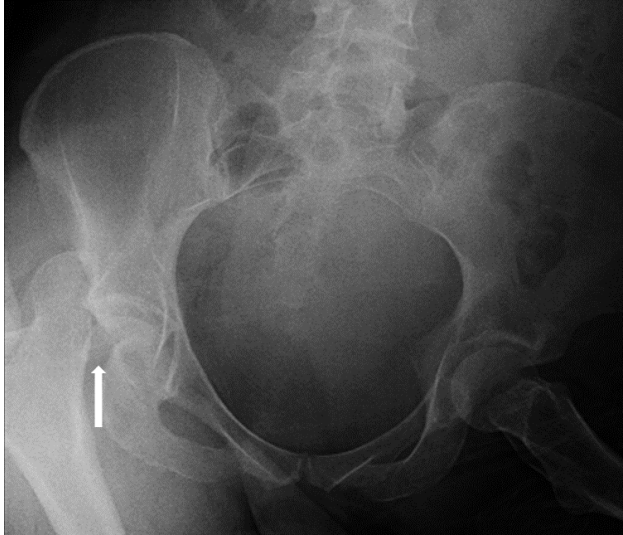


Figure 1. Pre-reduction radiograph demonstrating right sided posterior hip dislocation with inferior femoral head fragment (arrow) contained within the joint capsule

At this point, a decision to trial the ‘Hamilton Deadlift’ was made. With the stretcher positioned just above knee height (relative to the physician), the supine patient was slid to the edge of the stretcher closest to the physician in order to optimize mechanical advantage whilst performing the technique. With feet shoulder-width apart and a neutral back, the physician bent at the knees and waist into a stable position resembling the starting position of a deadlift (Fig. 2). At this point, the patient’s dislocated hip was flexed, and the dislocated leg was draped over the physician’s neck and upper trapezius muscles. With the physician’s upper back acting as the fulcrum, the physician grasped the patient’s ipsilateral ankle and flexed the patient’s knee to 30 degrees. The physician’s opposite hand was placed on the anterior superior iliac spine to provide counter traction against the patient’s pelvis. In this instance, a second individual was not needed to provide counter traction. The patient’s lower leg was moved away from midline to produce internal rotation of the hip. The physician then generated in-line traction by extending at the knees and hips. Like most other techniques, the combination of in-line traction, hip flexion, adduction and internal rotation was used for reduction. Upon application of this technique, a palpable shift of the femur was appreciable and an audible ‘clunk’ was heard. The hip was examined and found to be clinically reduced and stable to flexion and external rotation.

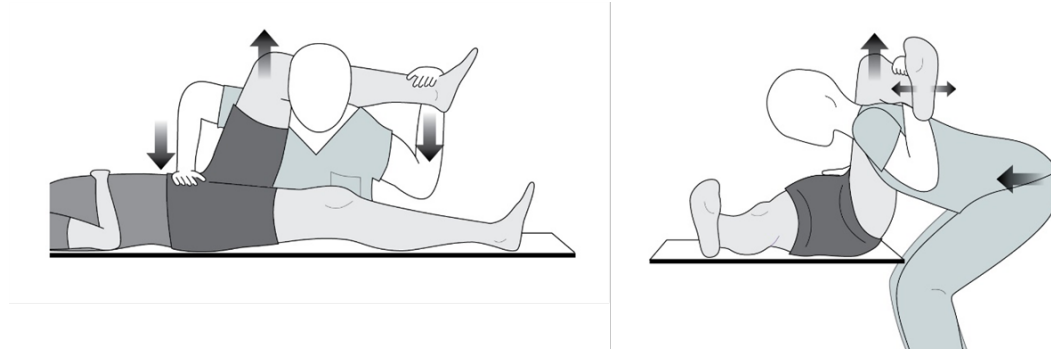


Figure 2. The “Hamilton Deadlift” technique. Arrows indicate force vectors. The patient’s lower leg can be manipulated (smaller arrows) to produce internal or external rotation at the hip. The physician may be positioned on the ipsilateral (pictured) or contralateral side.

After successful reduction, a thorough examination of ipsilateral long bones, knee ligaments, and ankle integrity was performed rule out iatrogenic injury. Neurovascular status was also assessed and found to be intact. Post-reduction CT imaging confirmed anatomic reduction of the hip (Fig. 3). The risks and benefits of operative management was discussed with the patient—she decided to undergo open reduction and internal fixation of the humerus and femoral head. Fixation of the Pipkin Type 1 femoral head fracture was performed using counter-sunk headless cannulated screws (Fig. 4). The patient’s course in hospital was uneventful. Three weeks following surgery, the patient had full range of motion in the hip. Ten weeks following surgery, she began full weight-bearing movement. At one-year follow-up, the patient had full hip strength and range of motion relative to her uninjured side with no complications.

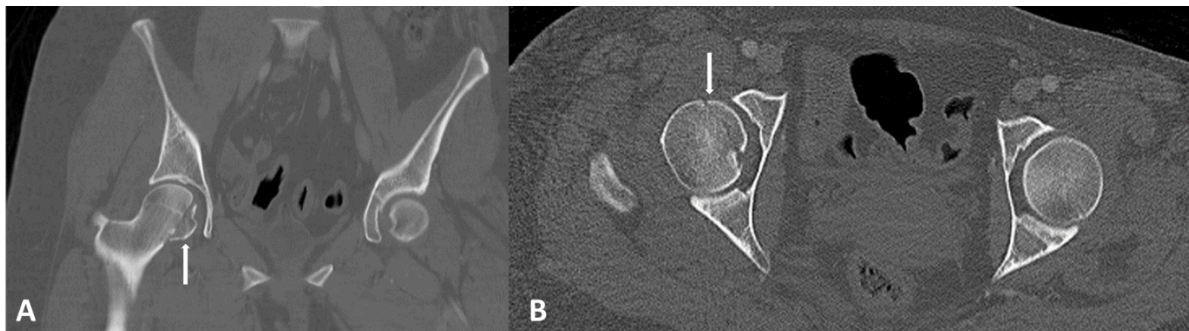


Figure 3. Post-reduction coronal (A) axial (B) CT images demonstrating successful reduction of right-sided posterior hip dislocation using the “Hamilton Deadlift”. A femoral head fracture (arrow) and the intact posterior wall of the acetabulum are also seen

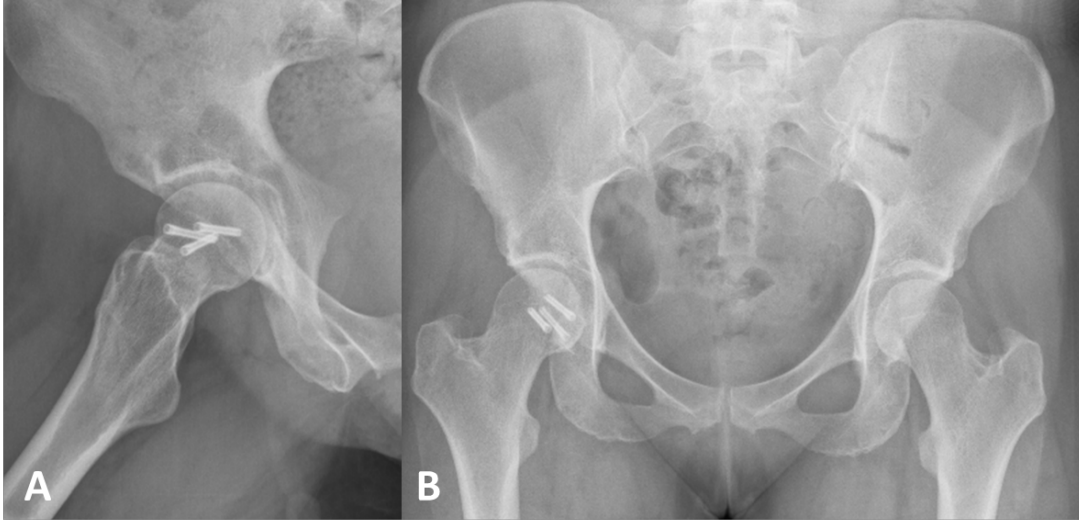


Figure 4. One-year post-operation radiographs demonstrating healed femoral head fracture with three cannulated screws in-situ. No heterotopic ossification or avascular necrosis is noted.

Discussion

This case-report is the first description of the “Hamilton Deadlift”, an original reduction technique for posterior hip dislocations. There are several advantages to this novel technique (**Table 1**). First, his technique generates force primarily through hip extension, with assistance from the paraspinal muscles. In contrast, the ability to perform other techniques (e.g. Allis, ‘Captain Morgan’) is often limited by the physician’s upper body musculature and/or an inability to grasp the injured lower extremity firmly. By using large muscle groups, a large amount of force may be generated with our technique without additional effort on behalf of the physician; this may be beneficial in patients with abundant hip girdle musculature (e.g. athletes, heavy individuals) or those with muscle spasm despite adequate sedation (4). =. Second, by assuming a position resembling a deadlift, free of lateral bending and awkward twisting, physicians may benefit from the motor memory of a familiar movement pattern (17). Finally, the patient remains fully supine throughout the reduction, which benefits patients with upper or contralateral lower-limb injury, cardiopulmonary insult, and/or polytrauma (18). A supine position also avoids the risk associated transferring a sedated or anesthetized and ventilated patient to a lateral or prone position (18).

However, given that this method requires force transfer through the spine, this technique may present difficulties for physicians with pre-existing back pathology. Additionally, due to the potentially forceful nature of the “Hamilton Deadlift”, caution should be exercised in patients with ipsilateral fractures about the hip or in non-native hips where a gentler technique is likely adequate (14, 16). Finally, it should be noted that it is theoretically possible to cause iatrogenic injury to the patient’s knee following improper application of this technique. Iatrogenic femoral neck fracture due to reduction has been reported with other techniques in the literature and is a potential complication of this technique if improper positioning is used (19).

Table 1. Advantages and disadvantages of the ‘Hamilton Deadlift’ for posterior hip dislocation

Advantages	Disadvantages
One person technique	Iatrogenic injury potential with overly-forceful reduction
Large force generation capacity	Physician at ergonomic disadvantage
Familiar movement pattern	Limited use in physicians with pathology involving the thoracolumbar or lumbar spine
No lateral bending or trunk rotation	
Supine patient	

This maneuver may be performed from either the injured or the uninjured side of the patient. When performed from the uninjured side, adduction of the injured hip is greater, which may increase the likelihood that the femoral head clears the posterior acetabular rim. Adduction of the injured hip may be increased by elevating the contralateral hip with padding or by leaning further over the patient’s midline toward their uninjured hip (if standing on the patient’s injured side). This new method removes the need for a physician to stand on a bed or stretcher, thereby reducing the risk of falls. The “Hamilton Deadlift” also has the unique benefit over of removing the need for a second individual to provide counter-traction. This may expedite reduction, an important benefit considering timely reduction has been shown to reduce the risk of femoral head osteonecrosis and sciatic nerve injury (7–9).

The “Hamilton Deadlift” is indicated for situations where it is difficult to grip the leg of the patient or when the patient has failed other reduction techniques (**Table 2**). Proposed contraindications of this technique are similar to other techniques utilizing the patient’s leg as a lever including ipsilateral long bone fracture, adjacent pathologic bone lesions, and extensive knee injury.

Table 2. Proposed indications and contraindications for use of the ‘Hamilton Deadlift’

Indications	Contraindications
Posterior dislocation of native hip	Ipsilateral long bone or femoral neck fracture
Suspected difficult reduction	Gross ipsilateral knee instability
Failed other technique	Unstable pelvic ring injury
Difficult to grip patient leg	Pathologic bone lesion(s) of ipsilateral femur

Conclusion

This case-report describes the first application of the “Hamilton Deadlift”, a novel reduction technique for posterior hip dislocations. The technique involves deadlift-like positioning and placing the patient’s leg over the physician’s upper back. The “Hamilton Deadlift” may be useful in difficult posterior hip reductions where more force generation is

required or when physician's upper body musculature and ability to grip the injured leg prevent application of more traditional methods.

Since this is a new technique, more cases are needed to further elucidate the advantages and disadvantages of the "Hamilton Deadlift" compared to other accepted closed reduction techniques. A case-control study comparing this technique to other techniques in the case of previous failed closed reduction would be greatly beneficial to further explore the efficacy and safety profile of this technique. Nevertheless, this case report provides strong preliminary evidence that the "Hamilton Deadlift" is a useful technique in difficult posterior hip dislocations that might otherwise require surgical intervention.

Declarations

Consent for publication

Consent for case publication was obtained from the patient prior to submission.

References

1. Clegg TE, Roberts CS, Greene JW, Prather BA. Hip dislocations—Epidemiology, treatment, and outcomes. *Injury*. 2010;41:329–34.
2. Beebe MJ, Bauer JM, Mir HR. Treatment of hip dislocations and associated injuries: current state of care. *Orthop Clin*. 2016;47:527-49.
3. Sanders S, Tejwani N, Egol KA. Traumatic hip dislocation-a review. *Bull NYU Hosp Jt Dis*. 2010;68:91–6.
4. Brooks RA, Ribbans WJ. Diagnosis and imaging studies of traumatic hip dislocations in the adult. *Clin Orthop Relat Res*. 2000;377:15-23.
5. Tabuenca J, Truan JR. Knee injuries in traumatic hip dislocation. *Clin Orthop Relat Res*. 2000;377:78–83.
6. Sahin V, Karakaş ES, Aksu S, Atlihan D, Turk CY, Halici M. Traumatic dislocation and fracture-dislocation of the hip: a long-term follow-up study. *J Trauma*. 2003. 1;54:520–9.
7. Hillyard RF, Fox J. Sciatic nerve injuries associated with traumatic posterior hip dislocations. *Am J Emerg Med*. 2003;21:545–8.
8. Ahmed G, Shiraz S, Riaz M, Ibrahim T. Late versus early reduction in traumatic hip dislocations: a meta-analysis. *Eur J Orthop Surg Traumatol*. 2017;27:1109–16.
9. Hougaard K, Thomsen PB. Traumatic posterior dislocation of the hip--prognostic factors influencing the incidence of avascular necrosis of the femoral head. *Arch Orthop Trauma Surg*. 1986;106:32–5.
10. Allis O. The Hip. Philadelphia, PA: Dorman; 1895. 14–26 p.

11. Bigelow J. On the dislocated hip. *Lancet*. 1878;1:894–5.
12. Robinson MK. The East Baltimore Lift: a simple and effective method for reduction of posterior hip dislocations. *J Orthop Trauma*. 1999;13:461.
13. Hendey GW, Avila A. The Captain Morgan Technique for the Reduction of the Dislocated Hip. *Ann Emerg Med*. 2011;58:536–40.
14. Waddell BS, Mohamed S, Glomset JT, Meyer MS. A detailed review of hip reduction maneuvers: a focus on physician safety and introduction of the Waddell technique. *Orthop Rev (Pavia)*. 2016;21;8:6253.
15. Bassi JL, Ahuja SC, Singh H. A flexion adduction method for the reduction of posterior dislocation of the hip. *J Bone Joint Surg Br*. 1992;74:157–8.
16. Dan M, Phillips A, Simonian M, Flannagan S. Rocket launcher: A novel reduction technique for posterior hip dislocations and review of current literature. *Emerg Med Australas*. 2015;27:192–5.
17. Adkins DL, Boychuk J, Remple MS, Kleim JA. Motor training induces experience-specific patterns of plasticity across motor cortex and spinal cord. *J Appl Physiol*. 2006;101:1776–82.
18. Yang EC, Cornwall R. Initial treatment of traumatic hip dislocations in the adult. *Clin Orthop Rel Res*. 2000;377:24-31.
19. Polesky RE, Polesky FA. Intrapelvic dislocation of the femoral head following anterior dislocation of the hip. A case report. *J Bone Joint Surg Am*. 1972;54:1097–8.