

Original Research Article

Atypical euthyroid presentation of steroid responsive encephalopathy with associated thyroiditis

Vineeth Bhogadi¹ and Arlene Kelly-Wiggins²

¹Michael G. DeGroot School of Medicine, McMaster University

²Geriatric and Memory Disability Clinic, Dalhousie University Faculty of Medicine

Abstract

Introduction

Steroid-responsive encephalopathy with associated thyroiditis (SREAT) is an autoimmune disease associated with antithyroid antibodies. Its clinical features are variable, ranging from sudden focal neurologic deficits to progressive sub-acute cognitive decline, and thus it can mimic a host of other neurological and psychiatric conditions.

Case Presentation

We present a case of a previously healthy 62-year-old female with rapid onset neurocognitive and functional decline. EEG and MRI findings were consistent with an encephalopathy of unknown origin. Serologic findings revealed elevated antithyroid antibodies but were otherwise insignificant.

Conclusion

Steroid-responsive encephalopathy with associated thyroiditis is typically a diagnosis of exclusion but should always be considered in cases of encephalopathy of unknown origin. The disorder is often underdiagnosed due to its variable presentation and poorly understood pathophysiology, but prognosis can be significantly improved with greater physician awareness and prompt management with corticosteroids.

Keywords: Hashimoto's, steroid-responsive, encephalopathy

Corresponding author: vineeth.bhogadi@medportal.ca

ISSN

DOI

Introduction

Steroid-responsive encephalopathy and associated autoimmune thyroiditis (SREAT), previously known as Hashimoto's encephalopathy, was first described by Brain and colleagues in 1966 (1). This condition is most often characterized by a subacute onset of confusion with an altered level of consciousness, myoclonus, and seizures but can have a wide range of clinical presentations (2). This particular case highlights an atypical presentation of SREAT and demonstrates the importance of thyroid function tests and anti-TPO antibody titers in the diagnosis of rapidly progressive encephalopathy.

Case Presentation

A 62-year-old previously healthy woman presented to our geriatric service with a 4-month history of progressive cognitive and functional decline. She had increasing forgetfulness and anhedonia. She also experienced a gradual loss of activities of daily living (ADLs) and instrumental activities of daily living (IADLs) over 30 days following initial presentation.

There was no history of previous cognitive decline, delirium, head injury, malignancy, or psychiatric symptoms such as delusions or hallucinations. Her relevant past medical history was significant for type II diabetes, hypertension, and angina. She had no history of substance use or recent travel.

On examination, she was ambulating independently without any aids. Her blood pressure was 176/95 mmHg and heart rate was 64 beats per minute. Pupils were equal and reactive to light, although further visual testing was difficult due to patient cooperation. Cogwheel rigidity was present in the upper extremities bilaterally and hypertonicity was present in the lower extremities bilaterally. Babinski's sign was positive on the right. Slight paratonia was noted in all four extremities, with maintenance of limb position and involuntary resistance. Muscle bulk and power were preserved. Her gait was wide based and uncoordinated with a tendency to extend backwards. Cerebellar testing was normal. Cardiovascular, respiratory, and abdominal examinations were grossly normal.

Cognitive testing revealed an MMSE of 14/30 and a MoCA of 8/30 with notable deficits in recall and orientation. The geriatric depression screen (GDS) was positive at 9/15.

Investigations

Complete blood count, extended electrolytes, liver function tests, renal function, and urinalysis were all within normal limits. HbA1c was elevated at 8.1%. Infectious disease work-up, including Syphilis IgG, HIV, Lyme disease, and Hepatitis B/C antibody titers were all negative. Anti-nuclear, anti-cardiolipin, p-ANCA, and c-ANCA antibodies were negative for an underlying autoimmune or vasculitic process. Paraneoplastic and voltage-gated potassium channel antibodies were all negative. Immunoglobulins G, A, and M were all within normal

range. Thyroid function tests showed TSH and free T4 to be within normal limits. Anti-thyroid antibodies (anti-TPO) were elevated at 1709 U/ml.

CSF was clear with normal opening pressure. CSF examination demonstrated elevated glucose at 4.62mmol/L, and total protein was normal. CSF serology was negative for herpes simplex virus and enterovirus. Creutzfeldt-Jacob disease workup was negative, including protein 14-3-3, h-Tau, and QuIC.

Electroencephalography (EEG) was abnormal with diffuse moderate-to-severe disturbance of the background with some predominance in the left frontotemporal region. Frontal intermittent rhythmic delta activity (FIRDA) was also noted at times (Figure 1). CT and MRI revealed moderate microvascular small vessel ischemia and mild mid-brain atrophy (Figures 2A; 2B). SPECT brain perfusion scan showed diffuse brain atrophy but no specific findings of note (Figure 2C).

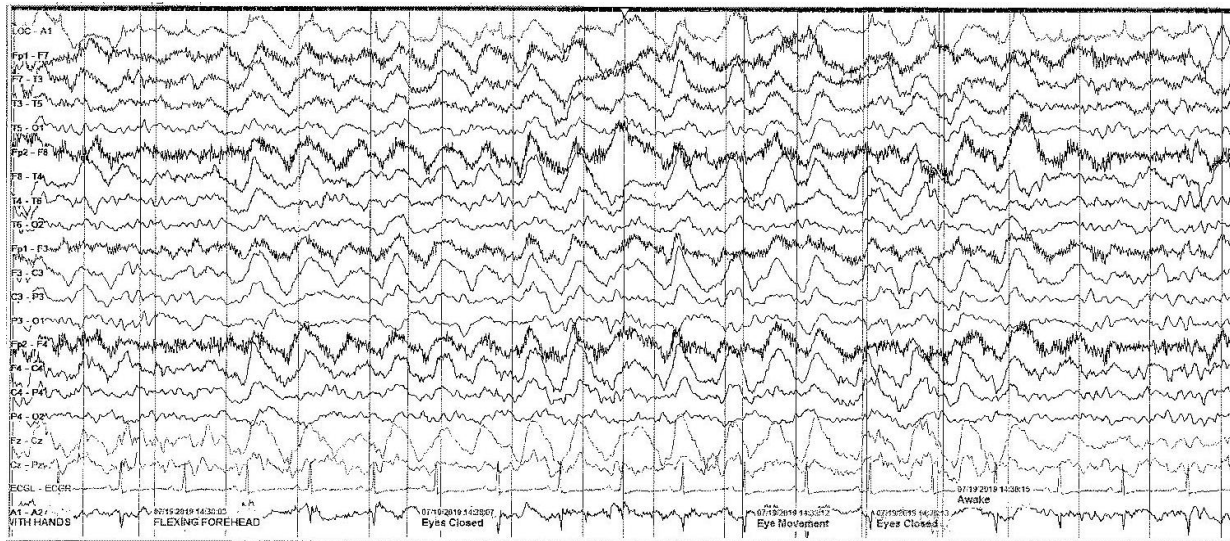


Figure 1. Electroencephalography (EEG) showing diffuse moderate-to-severe disturbance of the background with some predominance in the left frontotemporal region. Frontal intermittent rhythmic delta activity (FIRDA) also seen at times.

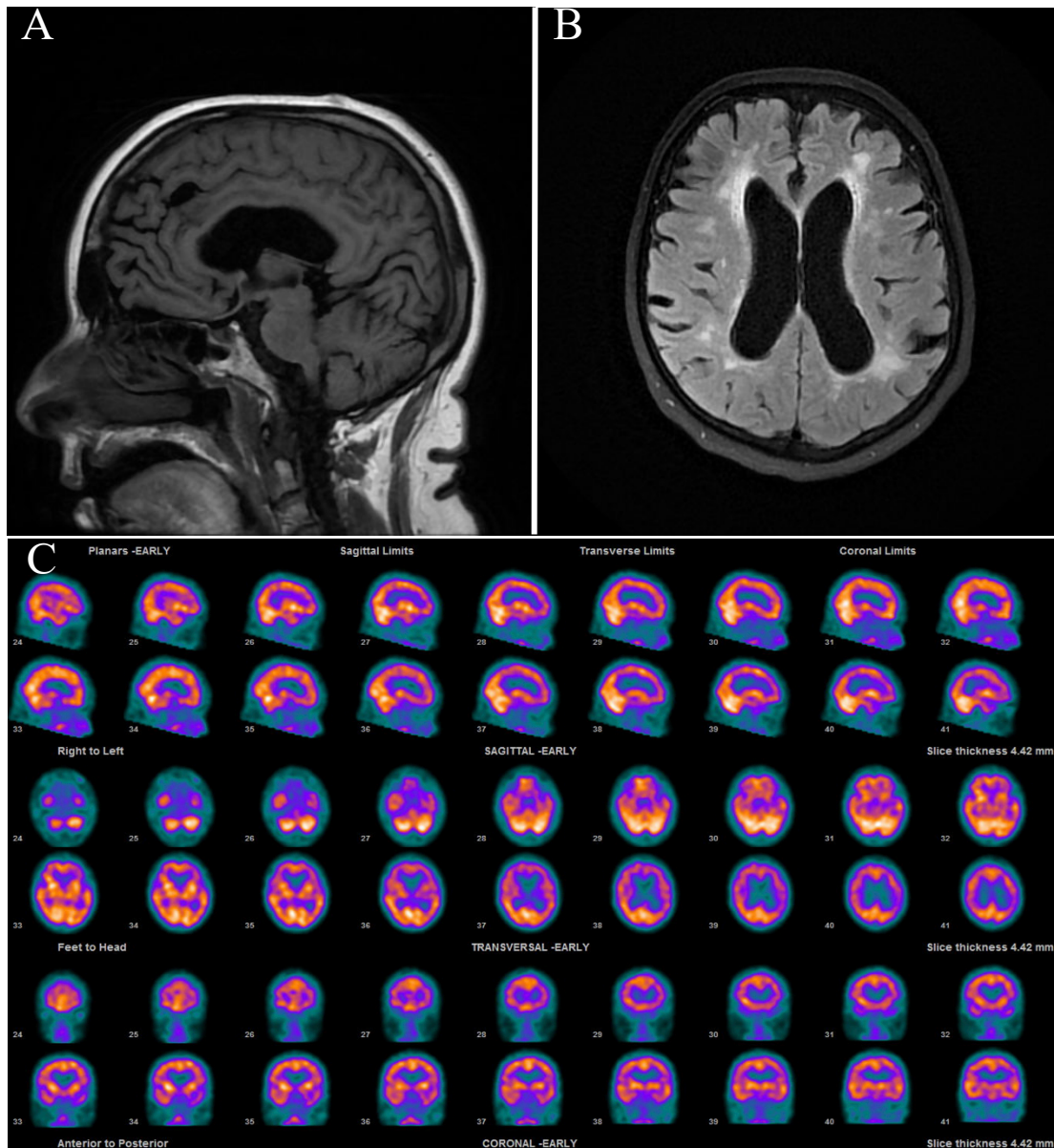


Figure 2. Magnetic resonance images (MRI) and SPECT images of the brain, demonstrating diffuse brain atrophy and small vessel ischemia. (A) T1 Flair sagittal MRI; (B) T2 Flair axial MRI; (C) SPECT brain perfusion imaging.

Treatment

Following the extensive work-up which revealed high anti-TPO antibodies, a diagnosis of encephalopathy of unknown origin was initially made, with consideration given to this being SREAT. The patient was started on 50 mg Prednisone PO at 1 mg/kg body weight for 6 days before being transitioned to a 12-week taper.

Outcome

At follow-up, the patient had dramatic improvement in cognitive status since initiation of steroid therapy, confirming the diagnosis of SREAT. She also had recovery in her functional status, with the patient able to manage some ADLs and IADLs independently.

Repeat cognitive testing demonstrated an improvement, with an MSSE of 21/30 and a MoCA of 13/30, but the patient was not yet at her cognitive baseline. There was worsening functional decline with ongoing steroid taper. As such, the decision was made to maintain her on high dose steroid therapy at 1 mg/kg body weight.

Discussion

SREAT is a controversial disorder with poorly understood etiology and pathogenesis. A systematic review on the subject in 2016 identified only 251 well-documented cases in the literature (2). This may in part be due to the variable presentation of the disorder, leading to it being underdiagnosed. Among the reported cases, the median age of onset is 52 years with females accounting for 73% of cases (2).

Clinical manifestations of SREAT are variable but most often include an acute or sub-acute onset of confusion accompanied by an altered level of consciousness. Two distinct patterns of presentation are noted to predominate: a stroke-like pattern with recurrent episodes of variable degree of cognitive decline and focal neurological deficits in 25% of cases, or a diffuse progressive pattern characterized by slowly progressive cognitive impairment with dementia, confusion, and hallucinations in the remaining 75% (3,4).

On laboratory investigations, a defining feature of SREAT is an elevated serum antithyroid peroxidase antibody (antiTPO Ab) or antithyroglobulin antibody (antiTg Ab) (2,5). However, thyroid function is variable amongst patients, with 25-35% of patients having subclinical hypothyroidism, 17-20% with overt hypothyroidism, and approximately 7% being hyperthyroid (4,5). Additionally, both serum and CSF titres of antiTPO/antiTg Ab have not been shown to correlate with the severity of the disease, and their sensitivity and specificity for SREAT is unknown (6). Thus, the exact pathogenesis is poorly understood, and it is unclear as to how the antiTPO/antiTg antibodies affect the brain. Much of the current evidence points towards the underlying pathophysiology being an autoimmune vasculitis, with immune complexes disrupting the cerebral microvasculature (7,8).

CSF is usually non-specific in suspected cases of SREAT. Analysis may reveal mononuclear pleocytosis in 20% of patients, whilst an elevated protein concentration occurs in 82% of patients (2). Similarly, EEG findings may be abnormal in 82% of cases with diffuse slowing consistent with encephalopathy as seen in our patient. MRI and CT imaging findings vary, with 49% of patients showing cerebral atrophy and non-specific white matter hyperintensities (2,4) as visualized in the current case. However, other individual case reports also note diffuse changes suggesting primary demyelination, meningeal enhancement, and T2 signal abnormalities in both hippocampi (5).

Our case presents more atypically with rapidly progressive cognitive impairment and no focal deficits, unlike the two well described patterns of presentation discussed above (3,4). Notably, the patient's manifestations did not concur with other common neurological symptoms associated with SREAT including tonic-clonic seizures (66% of patients), diffuse hyperreflexia (85% of patients), or myoclonus (38% of patients) (4). Additionally, our patient had no identifiable abnormalities on thyroid function tests and was euthyroid despite significantly elevated serum antiTPO Ab. This further highlights that the underlying mechanism of the condition is likely not related to thyroid status.

It is important to keep SREAT on the differential diagnosis for patients with focal neurologic deficits and acute cognitive changes given its rather variable clinical presentation. SREAT is a diagnosis of exclusion and, as such, Creutzfeldt-Jakob disease, meningoencephalitis, decompensating mixed dementia (Alzheimer's, Vascular), stroke and transient ischemic attack, cerebral vasculitis, and psychiatric diseases need to be excluded. Essential testing to exclude these diagnoses includes EEG, MRI, CSF analysis, and laboratory screening for usual causes of delirium as well as exclusion of an infectious etiology given the core immunosuppressive treatment.

Patients with SREAT respond dramatically to treatment with corticosteroids, with 91% of patients showing a partial or complete clinical response (2). However, there is no consensus as to the appropriate steroid dose, with oral prednisone doses ranging from 50-150mg daily and a median dose of 60mg/day (2). We found 50mg (1mg/kg) to be the optimal dose for our patient, with further dose titration causing a partial decline in cognitive function.

Long-term prognosis is variable, and residual cognitive impairment is seen in approximately 20% of patients (2,3). Our patient showed significant improvement in her neurocognitive status following the introduction of steroids, and progression of her cognitive deficits seems to be halted. This patient would be an excellent candidate for close follow-up to understand the dosage and duration of treatment with corticosteroids and to explore alternative immunosuppressant therapies in the future.

Conclusion

SREAT is a rare but underdiagnosed syndrome with a variety of clinical presentations. Our case highlights an atypical euthyroid presentation of SREAT despite significantly elevated antithyroid antibodies with non-specific EEG and MRI findings. This highlights the importance of testing antithyroid antibodies in patients with unexplained encephalopathy, along with the exclusion of other possible causes via CT, MRI, EEG, and serum and CSF analysis. A timely trial of corticosteroids is warranted in a patient with encephalopathy and elevated anti- thyroid antibodies without another obvious etiology.

Acknowledgements

We would like to thank the case study patient for granting permission for publication.

References

1. Brain L, Jellinek EH, Ball K. Hashimoto's disease and encephalopathy. *The Lancet*. 1966 Sep 3;288(7462):512-4.
2. Laurent C, Capron J, Quillerou B, Thomas G, Alamowitch S, Fain O, Mekinian A. Steroid-responsive encephalopathy associated with autoimmune thyroiditis (SREAT): characteristics, treatment and outcome in 251 cases from the literature. *Autoimmunity reviews*. 2016 Dec 1;15(12):1129-3.
3. Kothbauer-Margreiter I, Sturzenegger M, Komor J, Baumgartner R, Hess CW. Encephalopathy associated with Hashimoto thyroiditis: diagnosis and treatment. *Journal of neurology*. 1996 Aug 1;243(8):585-93.
4. Canelo-Aybar C, Loja-Oropeza D, Cuadra-Urteaga J, Romani-Romani F. Hashimoto's encephalopathy presenting with neurocognitive symptoms: a case report. *Journal of medical case reports*. 2010 Dec;4(1):337.
5. Chong JY, Rowland LP, Utiger RD. Hashimoto encephalopathy: syndrome or myth?. *Archives of Neurology*. 2003 Feb 1;60(2):164-71.
6. Ferracci F, Bertiato G, Moretto G. Hashimoto's encephalopathy: epidemiologic data and pathogenetic considerations. *Journal of the neurological sciences*. 2004 Feb 15;217(2):165-8.
7. Takahashi S, Mitamura R, Itoh Y, Suzuki N, Okuno A. Hashimoto encephalopathy: etiologic considerations. *Pediatric neurology*. 1994 Nov 1;11(4):328-31.
8. Philip, R., Saran, S., Gutch, M., & Gupta, K. (2014). An unusual presentation of Hashimoto's encephalopathy. *Indian journal of endocrinology and metabolism*, 18(1), 113.