
Neurofibromatosis Type 1 in Past Populations: Detection and Impact of the Disorder

Elizabeth Finnis

*Department of Anthropology
McMaster University*

Abstract: Neurofibromatosis type 1 (NF1) is a dominant autosomal disorder with a variety of clinical manifestations, mild to severe, including cutaneous growths and colourings, skeletal changes, and possible mental disabilities. There is evidence, in the form of historical medical records, that NF1 existed in past populations, and yet the condition does not appear to be of interest to paleopathological researchers. This may be due to a lack of interest in the area, but also may be a result of a poor understanding of the possible skeletal manifestations of the disorder. Various recent clinical studies have discussed such possible changes, and these may be useful for the paleopathologist in diagnosing possible cases of NF1 in past populations. Additionally, the cloning of the gene that controls the disorder has allowed for the study of the sequence. This could allow for the use of the polymerase chain reaction (PCR) technique in the study of ancient DNA to give a more definite diagnosis of the disorder in individuals who seem to display the skeletal indicators of NF1. However, an understanding of the macroscopic, skeletal indicators of NF1 is important for the paleopathologist. Additionally, examining the past for evidence of this disorder may reveal some insight into its origins, as well as reveal information about the coping strategies of individuals who may have been functionally compromised and the attitudes of communities about disabilities.

Introduction

While the name Joseph Merrick may be unknown to the general public, his designation as 'The Elephant Man' is more widely known. The tragic disfigurement of Merrick's hand and face evokes a picture of horror among many. The early classification of Merrick's condition was Neurofibromatosis 1, a disorder that results in numerous central and peripheral nerve sheath tumours, among other symptoms. However, work done within the last ten years has revised this diagnosis to a rare disorder called Proteus Syndrome (Carswell 1997:5). This raises the question of whether Neurofibromatosis 1 (NF1) could be recognised in a paleopathological context. There are several impacts on past populations that both mild and severe

cases of NF1 may have had on the affected individual and possibly the community. Among such impacts could be a poor self image and resulting isolation, an inability to contribute to community activities, and innovative coping strategies.

Understanding the impact of NF1 and its development in past populations may allow for a more complete understanding of cultural attitudes about issues such as deformity and the value of the individual to the community. However, in order to determine whether NF1 was a problem in the past, it is necessary to investigate the bony changes and effects that the disorder has on the individual. This paper focuses on the skeletal changes that may be indications of NF1 as well as some potential difficulties the afflicted individual in the past may have experienced. Furthermore, current techniques in paleopathological research, such as ancient DNA studies, may aid in an accurate diagnosis of NF1 in past populations. Since an investigation into the paleopathological literature revealed little, if any mention of NF1, clinical perspectives and sources were relied upon.

History and Manifestation

While NF1 was originally described by von Recklinghausen in 1882 (Ward *et al.* 1990: 943), there are earlier records that seem to indicate a possible diagnosis of NF1. The earliest recognised portrayal of the disorder comes from a Syrian illustration dated to the thirteenth century. Two additional early descriptions come from the eighteenth century, one noted in 1785, referring to a patient who had growths, or 'wens' over his body; with the other mention coming in 1793 by a doctor who designated the affected patient as 'The Wart Man' (Mulvihill 1990: 3-4).

Neurofibromatosis 1 is an autosomal dominant disorder which is transmitted from generation to generation. In the present day, NF1 affects approximately 1 in 3000 people (Ward *et al.* 1990: 943), and affects both sexes in relatively equal numbers without any particular ethnic, geographic or racial distribution (Rubenstein and Yahr 1984:2). Since NF1 is a dominant autosomal disorder, each offspring of an affected individual has a 50% chance of expressing the trait (Carey 1990:170). It is interesting to note that approximately one half of affected individuals inherited the NF1 gene from an affected parent, while 30-50% of cases appear to be due to a spontaneous mutation (Carey 1990:174; Marchuk *et al.* 1991:931). The disorder itself has extremely variable clinical manifestations, with approximately 60% of affected individuals exhibiting mild forms such as cutaneous fibromas and *cafe-au-lait* spots on the skin. Another 20% of sufferers display currently correctable problems including surgically repairable spinal deformities, or leg deformities which require bracing. The remaining 20% exhibit serious and persistent problems (Rubenstein and Yahr 1984:5). It should be noted that the more severe impacts of NF1 tend to be present at birth.

In 1987, the NF1 locus was mapped on the long arm of chromosome 17 (Figure 1). Studies with NF1 linked markers have allowed for prenatal diagnosis of the condi-

tion through amniocentesis testing (Ward *et al.* 1990:943,948). In 1990, the NF1 gene was cloned allowing for a greater understanding and identification (Gasparini *et al.* 1993:415). The NF1 gene has been identified as containing 51 exons, and appears to be expressed across most human tissues (Viskochil *et al.* 1993:184-189).

There are numerous soft tissue effects associated with NF1, including the previously mentioned characteristic *café-au-lait* spots on the skin and soft tissue growths on peripheral and central nerves, called neurofibromas (Mulvihill 1990:1). These tumors of the nerve sheath can have a number of consequences for the affected individual including pain, numbness and weakness of the area (Martuza 1990:71). The neurofibroma is the most common tumor associated with NF1, and can develop anywhere in the body, at any stage in life (Rubenstein and Korf 1990:49). Other soft tissue effects include lisch nodules which are clumps of dark pigment cells located in the iris of the eye. These nodules usually first appear in late childhood (Korf and Carey 1990:19). However, except in rare occasions, such soft tissue manifestations would not be preserved, and are, therefore, not of much use for paleopathological diagnosis. Bone defects and changes, usually characteristic of the more severe forms of NF1, are more likely to be preserved; thus criteria discussed will focus on these features.

There are a number of bone defects that can be associated with NF1 including various skull defects. Megalencephaly, an increase in head size to well above average, but parallel in growth with the rest of the body, is a common feature of NF1 (Rubenstein and Korf 1990:40). Another skull defect that may be associated with the disorder is hydrocephaly, also an abnormal growth in head size, associated with a build up of cerebrospinal fluid in the skull cavity (Rubenstein and Korf 1990: 42). While additional skull defects are uncommon, two other changes can sometimes be seen with NF1. An absence of a portion of the sphenoid bone, usually in conjunction with a deformity of the orbit, is often manifest in NF1 affected individuals. An additional skull defect that can occur is a defect of the lambdoidal suture which most often occurs on the left side of the skull. This results in a gap at this junction which may enlarge during childhood. The cause of this defect is unknown (Rubenstein and Korf 1990:44).

Spinal deformities can also be displayed in NF1 patients, although estimates of this manifestation vary between 10 and 60% (Funasaki *et al.* 1994:692). Scoliosis, a lateral curvature of the spine, is often a feature of children with NF1, usually showing before the age of 10. This curvature can be manifest in two ways: the more common C-shaped curve, involving eight to ten vertebrae, can also be caused

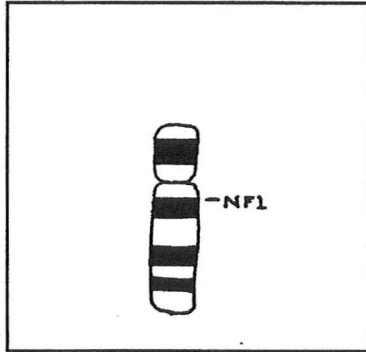


Figure 1. A map of chromosome 17 illustrating the approximate location of the NF1 gene. (Adapted from Korf and Carey 1990:180).

by numerous other conditions; or a far less common sharp angular curvature usually involving five vertebrae or less. This type of curvature is found almost exclusively in people with NF1, and is often accompanied by a cervical deformity. This lateral curvature can be accompanied by kyphosis of the spine, a front to back curvature which can result in a severe spinal deformity (MacEwan 1990:125-127). It has been noted that tumors of the neural sheaths can occur in the spine. As a result, the affected area may display wider interspinal foramina (Ortner and Putschar 1981:325).

Possibly associated with kyphosis and scoliosis can be rib penciling, vertebral scalloping and apical wedging (see Figure 2). One clinical study (Funasaki *et al.* 1994) examined the likelihood of such bony changes in patients with NF1 using radiographic images. Rib penciling, considered to be present when the width of a rib was smaller than that of the narrowest portion of the second rib, was found to be present in 84% of the measurable study group with a thoracic curvature. Additionally, 48% of the group that could be measured exhibited vertebral scalloping, with the depth of the scalloping being no less than three millimetres in the thoracic region, and four millimetres in the lumbar region (Funasaki *et al.* 1994:693-696). Neurofibromas on the skin of the individual affected by NF1 can be purely cosmetic problems. However, they are also associated with the overgrowth of the bone in the surrounding area which can cause an enlargement of the face, arms, hands, or legs (Rubenstein and Korf 1990:47). In the leg, the femur, tibia and

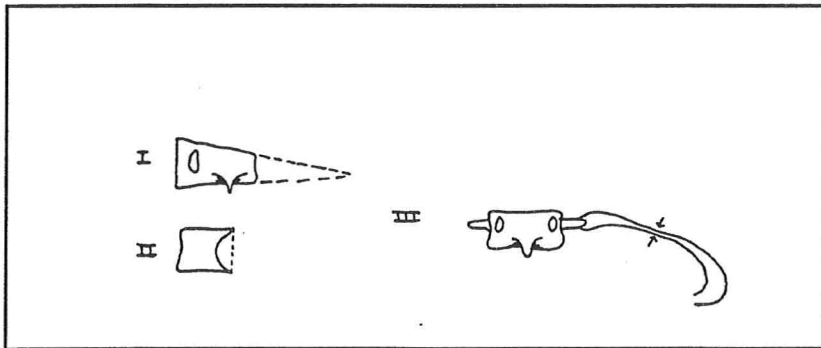


Figure 2. Illustration of apical wedging (I), vertebral scalloping (II) and rib penciling (III). (Adapted from Funasaki *et al.* 1994:694). The depth of the vertebral scalloping was measured from the posterior edge to the deepest point of the scalloped vertebra. The width of the rib penciling was measured at the narrowest portion of the rib. The angle of vertebral wedging was formed by two lines drawn at the ends of the vertebra along the end plate, as illustrated.

fibula can all become thicker and larger on one side of the body due to tumor development, which may result in unequal leg lengths. Paradoxically, individuals with a more severe form of NF1 may exhibit extremely thin bones, especially in the tibia, causing the affected long bone to be far more fragile, and subject to fracture and deformity. Anterolateral bowing of the tibia may be a result of such thin-

ning (MacEwan 1990: 134).

In addition to bony overgrowths, thinning and bowing, there are other severe limb deformities that can sometimes occur in the NF1 afflicted individual. Such growth disturbances may lead to serious functional impairment. For example, the individual who suffers knee or ankle joint tumours may have compromised mobility. In such cases, amputation of the affected area may be the best course since a prosthesis of some sort may offer better movement possibilities (MacEwan 1990:136).

Identification and Differential Diagnosis

While the soft tissue effects of NF1 will very rarely be preserved in the skeletal record, the bony changes discussed above may be preserved. In searching for evidence of NF1 in past populations, simply finding one of the discussed skeletal manifestations, with the possible exception of the sharp angular spinal curve, would not be sufficient for a diagnosis since many of these changes may be a result of other conditions.

Hydrocephaly is rare in the paleopathological record, and other possible causes can be toxoplasmosis, a parasitic infection, or viral infections such as mumps and measles (Roberts and Manchester 1995:42). Scoliosis and kyphosis of the spine are common conditions with NF1, but there are many other potential causes of such deformities. Compression fractures in the lumbar and thoracic spine may cause scoliosis, although in such cases, further evidence of fractures may also be displayed. In the case of compression fracture, the vertebrae may display a different appearance than NF1 affected patients (Roberts and Manchester 1995:77). Scoliosis can also be a result of rickets which can cause the demineralisation of the vertebral bodies and compression of the vertebrae (Steinbock 1976:270). Tuberculosis may also be a potential cause of kyphosis and scoliosis in the spine. However, in such instances, a diagnosis of NF1 could be precluded by, among other signs, a radiograph of the rest of the skeleton searching for evidence of TB abscess formation in the cancellous tissue of the metaphyses (Steinbock 1976:181,186).

Deformities of the tibia and other long bones may be mistaken for other neoplastic benign growths, while thinning of the bones may be mistaken for rickets. A difference in the length of the tibia may present a good initial indication towards a diagnosis of NF1.

It seems that severe lower limb deformities, along with an absence of the sphenoid wing in the skull, rib penciling and the sharp scoliosis of the spine, along with the possibility of wider foramina of the affected areas, may be the most likely combination of skeletal changes that suggest a diagnosis of NF1. However, an accurate diagnosis of the disorder would need an almost entirely intact skeleton. Additionally, many of the different deformities that may appear within the skeleton of the

NF1 affected individual might be the result of other problems. Thus, what appears to be a case of NF1 may also be a combination of trauma and other conditions or illnesses. It is for this reason that a combination of the most important skeletal changes mentioned above would be most useful to give an initial suggestion for a diagnosis of NF1.

With the mapping of the NF1 gene on chromosome 17, and its cloning, the possibility for DNA amplification in a suspected NF1 affected individual is available. DNA testing is an area that is growing in popularity, with many applications, including a more accurate diagnosis of conditions which exhibit a clear relationship with a specific gene. The polymerase chain reaction (PCR) technique for DNA studies has been used for prenatal diagnosis of NF1 in current populations (Rodenhiser *et al.* 1993:363). Ancient DNA research has demonstrated how the PCR technique can be used to amplify and examine DNA fragments from the skeletal remains of past populations. The amplification of sections of DNA has been successfully accomplished on ancient human skeletal remains (Paabo 1993: 91), and has a direct application in attempting to diagnose NF1. Although the process of ancient DNA amplification is more time consuming than DNA extraction from soft tissues, due to the preparation time required for the bone, PCR amplification would be useful to provide a definite diagnosis of NF1 when skeletal changes suggest the disorder, but may also be a result of other problems. It must be remembered, however, that the PCR technique is extremely sensitive to contamination, and extra precautions must be taken to prevent this (Paabo 1993: 90). Additionally, it is important to note that in order to justify DNA testing, skeletal clues suggesting a likely diagnosis of NF1 would be necessary. Such skeletal indications, as discussed above, would provide the researcher with the initial suggestion of NF1 in past individuals and past populations which could then be confirmed through DNA testing.

Another factor to consider is that of sample availability. Since only 20 to 40% of individuals with NF1 exhibit severe consequences, which presumably means skeletal changes, the ratio of affected individuals who had the disorder and could possibly be diagnosed by the paleopathologist is greatly reduced. The chances of locating an affected individual are increasingly reduced when factors affecting sample availability are considered: the proportion of individuals in a population buried at archaeological sites, the proportion preserved, and the proportion discovered and recovered (Waldron 1994:12-16). As well, some of the bony changes that may be a result of NF1 may especially affect preservation. Extreme thinning of the bones may have resulted in multiple fractures, possibly weakening the bone, reducing the chances of good preservation.

Impact on Past Populations

Since NF1 can be an inherited autosomal disorder, it is reasonable to assume that past populations would have had a similar proportion of NF1 cases to modern pro-

portions. Historical medical records have suggested that there were individuals affected by this disorder in the past. As previously mentioned, NF1 has variable manifestations with the majority of cases being milder forms. More severely affected individuals in the past would most likely have been faced with some daunting challenges. It should be noted here that while 20% of modern cases exhibit correctable problems, due to current medical techniques which allow for processes from plastic surgery to spinal corrections, past populations may not have had such techniques. As a result, such currently correctable symptoms of the disorder would most likely have been untreatable and, thus, a larger proportion of more serious cases may have prevailed.

Development of hydrocephaly after the fusion of the fontanels has been completed can have correlated problems due to the build up of the cerebrospinal fluid in the skull cavity. Vomiting, lethargy, double vision, and headaches may have plagued the victim with this manifestation. Extreme cases may even have resulted in the death of the individual (Rubenstein and Korf 1990:42). While hydrocephaly can be treated today by placing a shunt under the skin, draining the excess fluid in the skull to the abdomen (Martuza 1990:78), it seems highly unlikely that past populations would have had such technology at their disposal. Similarly, current treatments for scoliosis, such as bracing and spinal surgery, would likely have been unknown in the past. Untreated scoliosis can result in severe spinal deformities and a loss of mobility, while cervical kyphosis can result in a pressure on the spinal cord, possibly resulting in pain, numbness or paralysis (MacEwan 1990:130-131).

Mobility problems may also have been faced by those individuals who displayed different limb lengths, extreme thinning of the long bones, or severe tumours in the leg area. Evidence for amputation in the past is generally extensive (Steinbock 1976:36), and it is quite possible that early populations may have recognised that in the case of severe limb complications, amputation may have been the most pragmatic solution, to allow for greater movement with some sort of prosthesis or crutch. The thinning and bowing of the leg bones, with the resulting increased fragility of the bone, may also have rendered some serious problems, unless braces were recognised as necessary, and could be manufactured. The affected individual may have been forced to rely on others for food gathering and aid in movement.

Bony changes as a result of NF1 may not have been the only disabling effects on the affected individual (Table 1). Aside from possible social isolation and a loss of the function of the limbs as a result of disfiguring and cumbersome neurofibromas, there are numerous other problems related to soft tissue manifestations of NF1. The location and the size of the neurofibromas may have created communication problems for the affected individual. For example, neurofibromas in the neck region may affect the quality of the voice, also slowing speech rates. Neurofibromas on the tongue may burden tongue mobility, thus affecting articulation (Solot *et al.* 1990: 61).

There is also the possibility that reasonably uncommon optic nerve tumours could

<i>Structural</i>	<i>Functional</i>
Megalencephaly	Seizures
Hydrocephaly	Learning Disabilities
Absence of Sphenoid wing in skull	Mental Retardation (rare)
Lambdoidal Suture defect	Speech Disorders
Spinal deformities	
Extreme thickening/thinning of long bones	

Table 1. *Some developmental anomalies of the nervous system associated with Neurofibromatosis Type 1. (From MacEwan 1990:136; Rubenstein and Korf 1990:41,47; and Solot et al. 1990:61).*

result in failing vision, while the far more common acoustic nerve tumours could cause tinnitus, dizziness and progressive hearing loss. Additionally, although rare, and occurring less than one percent of the time in NF1 affected individuals, mental retardation, or possibly learning disabilities and epilepsy may result from tumours of the central nervous system. There is also a higher risk for malignant brain tumours (Rubenstein and Yahr 1984:7-8; Rubenstein and Korf 1990:42). Such factors may have contributed to a reduced lifespan of the affected individual, and would doubtless have been difficult to cope with in past societies, as they are today.

Individuals who were affected by NF1 in the past may have had some difficult problems, and who may not have been able to contribute in standard ways to the community, may have had other roles. Those who displayed limb deformities in hunting and gathering nomadic groups may have had a difficult time surviving, and it seems apparent that all severely afflicted individuals would have been dependent on others for aid in survival. However, since NF1 can be a slowly progressive condition, it is possible that some individuals may have been able to lead reasonably normal lives for some period of time. Additionally, it must be kept in mind that those who displayed the milder effects of the disorder, such as small neurofibromas, would have been quite capable of contributing to society, and were possibly more likely to pass on the gene for NF1 than the more seriously afflicted individuals.

Research Implications and Conclusion

Neurofibromatosis type 1 clearly exhibits numerous bone changes in the individual, although these do not appear to be specific or necessary to the condition. The scarcity of paleopathological literature on this subject may reflect a lack of interest in the subject area, or it may simply be that until recently, the condition was poorly understood and the bony changes were either unknown or understudied. A possible alternative explanation is that many of the bone changes that are a result of this

disorder have been mistaken for other conditions or diseases. However, these suggestions do not preclude study into the area of NF1. The potential problems that this condition displays may have created some interesting cultural adaptations along with some difficult challenges to the afflicted individual.

A potential, highly informative approach to the search for victims of NF1 in past populations may be through the examination of amputated remains found at archaeological sites. As Steinbock (1976:36) notes, there are numerous cases of amputation documented in paleopathological literature. Signs of healed amputation cases include the vascular erosion of the bone end and adjacent shaft of the amputated areas, the formation of an endosteal callus to narrow the exposed end of the marrow cavity, and the formation of osteophytes which may then fuse with the free ends of the amputated bones (Steinbock 1976:36). It could be extremely interesting to examine examples of amputation of the lower limbs in an attempt to determine whether or not the amputation was performed as a result of severe NF1 complications. However, in order to achieve a possible diagnosis of NF1, more than simply the amputated area would be necessary for study. An additional possibility for approaching the study of this issue could be to begin by examining intact skulls for a missing sphenoid wing and lambdoidal suture defects. In cases where skeletal indications cause NF1 to be a suspected diagnosis, DNA testing could be used to confirm the suspicion. It is also interesting to note that since NF1 can be an inherited disorder, members of the same family were likely to have been affected. If several cases of NF1 are found in one sample, such cases may be useful in tracing family ties. However, it is important to remember that the disorder can also arise as a spontaneous mutation. Thus, the manifestation of NF1 in several individuals from one mortuary sample may not always indicate a close familial relationship.

It is clear from modern cases of NF1 that there can be numerous possible effects on the individual with the disorder. Living with some of the more serious forms of NF1 would have been a difficult undertaking, both physically and emotionally, in past populations. Since NF1 can be an inherited disorder of fairly common occurrence, it seems highly likely that past populations would have exhibited cases of this disorder, especially in affected family units. Investigation into the history of this disorder may give some interesting information on the origin of the condition, as well as cultural responses to afflicted individuals and disabilities on the whole. Using some of the skeletal changes that have been discussed in this paper may allow for an initial diagnosis of NF1. Furthermore, the potential for DNA testing of samples of possible NF1 cases may allow for more accurate diagnosis of the disorder.

* * * * *

References Cited

- Carey, J.C.
1990 The Genetics of Neurofibromatosis.
In *Neurofibromatosis*. Pp. 163-177.
A.E. Rubenstein and B.R. Korf, eds.
New York: Thieme Medical Publishers, Inc.
- Carswell, H.
1997 Modern-day Imaging Lends New Dx to Elephant Man.
The Medical Post Jan 14: 5.
- Funasaki, H., R.B. Winter, J.B. Lonstein, and F. Denis
1994 Pathophysiology of Spinal Deformities in Neurofibromatosis.
Journal of Bone and Joint Surgery 76: 692-700.
- Gasparini, P., A. Grifa, P. Origone, D. Coviello, R. Antonacci, and M. Rocchi
1993 Detection of a Neurofibromatosis Type 1 (NF1) Homologous Sequence
by PCR: Implications for the Diagnosis and Screening of Genetic
Diseases.
Molecular and Cellular Probes 7: 415-418.
- Korf, B.R. and J.C. Carey
1990 Molecular Genetics of Neurofibromatosis.
In *Neurofibromatosis*. Pp. 178-200.
A.E. Rubenstein and B.R. Korf, eds.
New York: Thieme Medical Publishers, Inc.
- MacEwan, G.D.
1990 Orthopaedic Aspects of Neurofibromatosis.
In *Neurofibromatosis*. Pp. 125-142.
A.E. Rubenstein and B.R. Korf, eds.
New York: Thieme Medical Publishers, Inc.
- Marchuk, D.A., A.M. Saulino, R. Tavakkol, M. Swaroop, M.R. Wallace,
L.B. Anderson, A.L. Mitchell, D.H. Gutmann, M. Boguski, and F.S. Collins
1991 cDNA Cloning of the Type 1 Neurofibromatosis Gene: Complete
Sequence of the NF1 Gene Product.
Genomics 11:1931-1940.
- Martuza, R.L.
1990 Neurosurgical Aspects of Neurofibromatosis.
In *Neurofibromatosis*. Pp. 71-79.
A.E. Rubenstein and B.R. Korf, eds.
New York: Thieme Medical Publishers, Inc.
-

-
- Mulvihill, J.T.
1990 Introduction and History.
In *Neurofibromatosis*. Pp. 1-14.
A.E. Rubenstein and B.R. Korf, eds.
New York: Thieme Medical Publishers, Inc.
- Ortner, D.J. and W.G.J. Putschar
1981 *Identification of Pathological Conditions in Human Skeletal Remains*. Smithsonian Contributions to Anthropology 28.
Washington, D.C.: Smithsonian Institution Press.
- Paabo, S.
1993 Ancient DNA.
Scientific American 269: 86-92.
- Roberts, C. and K. Manchester
1995 *The Archaeology of Disease*.
New York: Cornell University Press.
- Rodenhiser, D.I., P.J. Ainsworth, M.B. Coulter-Mackie, S.M. Singh, and J.H. Jung
1993 A Genetic Study of Neurofibromatosis Type 1 in South-western Ontario.
II A PCR Based Approach to Molecular and Prenatal Diagnosis Using Linkage.
Journal of Medical Genetics 30: 363-368.
- Rubenstein, A.E. and F. Yahr
1984 *Neurofibromatosis-Information for Patients and Families*.
New York: The National Neurofibromatosis Foundation Inc.
- Rubenstein, A.E. and B.R. Korf
1990 Neurological Aspects of Neurofibromatosis.
In *Neurofibromatosis*. Pp. 40-54.
A.E. Rubenstein and B.R. Korf, eds.
New York: Thieme Medical Publishers, Inc.
- Solot, C.B., E.H. Zackai, A.C. Obring, D.F. Konkle, S. Handler, and A.T. Meadows
1990 Communication Disorders in Children with Neurofibromatosis Type 1.
In *Neurofibromatosis*. Pp. 59-70.
A.E. Rubenstein and B.R. Korf, eds.
New York: Thieme Medical Publishers, Inc.
- Steinbock, R.T.
1976 *Paleopathological Diagnosis and Interpretation*.
Illinois: Charles C. Thomas Pub.
-

- Viskochil, D., R. White, and R. Cawthon
1993 The Neurofibromatosis Type 1 Gene.
Annual Review of Neuroscience 16: 183-205.
- Waldron, T.
1994 *Counting the Dead*.
Chichester: John Wiley and Sons Ltd.
- Ward, K., P. O'Connell, J.C. Carey, M. Leppert, S. Jolley, R. Plaetke, B. Ogden,
and R. White
1990 Diagnosis of NF1 by Using Tightly Linked Flanking DNA Markers.
American Journal of Human Genetics 46: 943-949.